



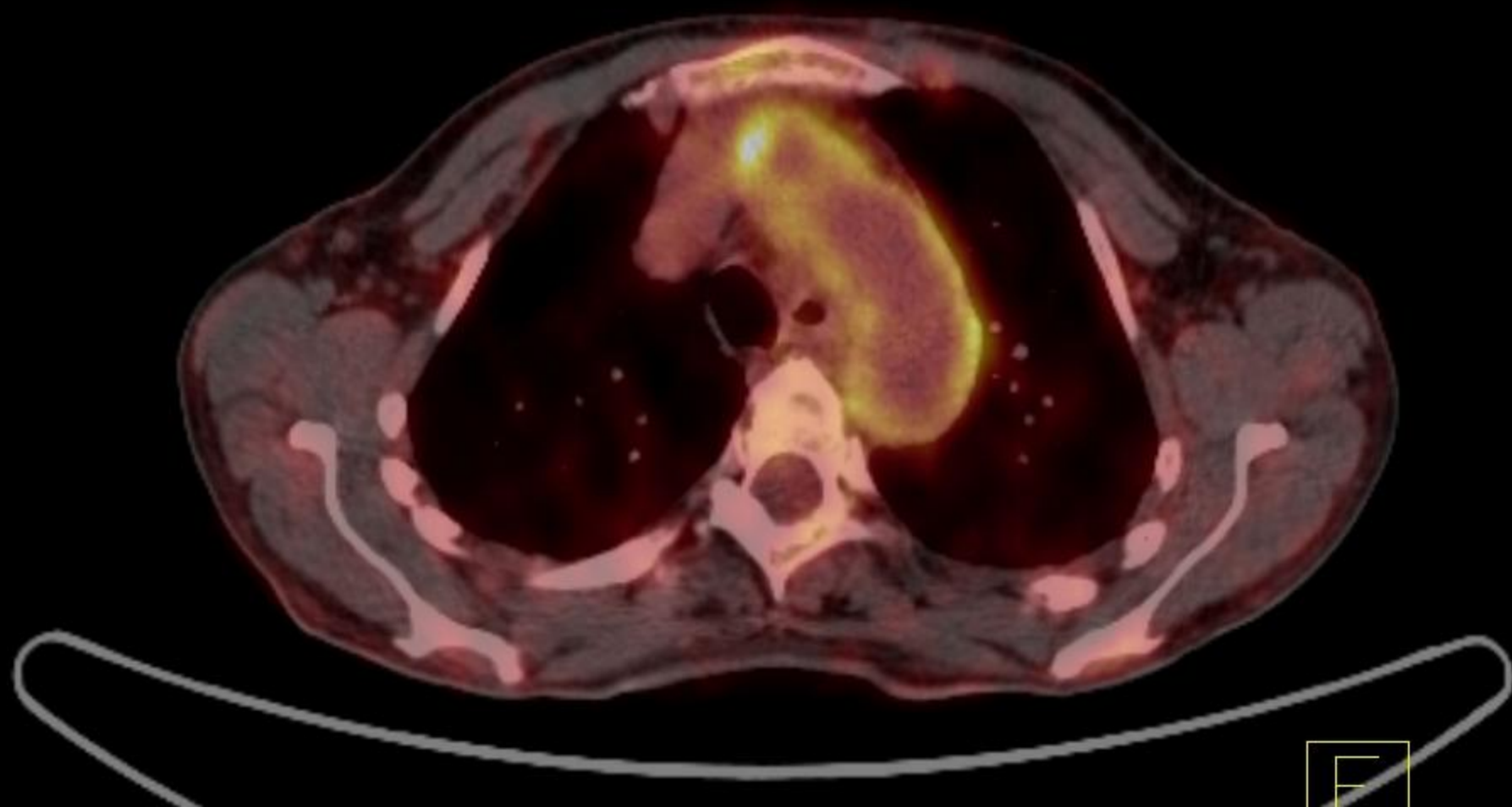
**J.GIRON P.FAJADET**

Homme de 45 ans

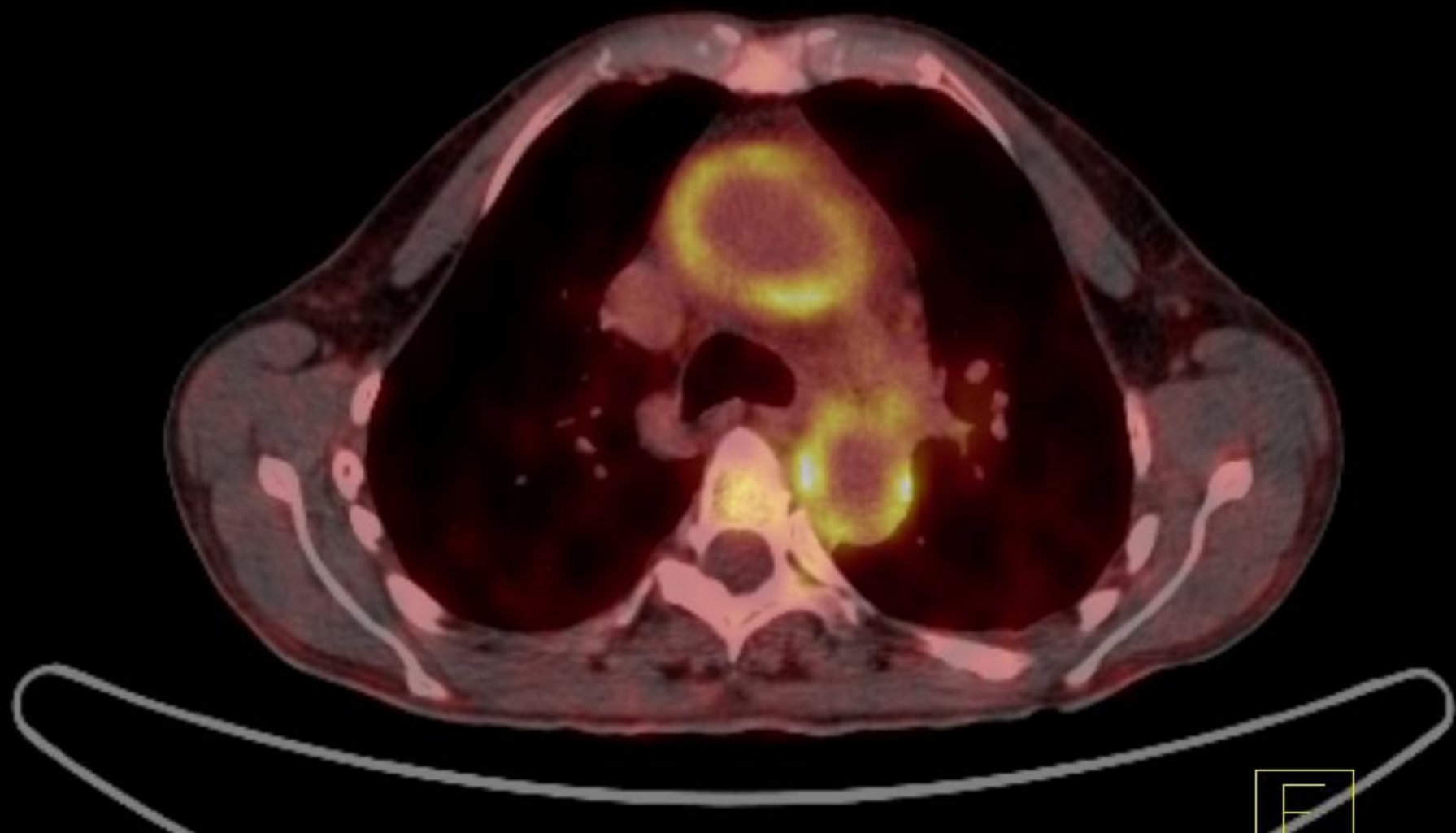
AEG , syndrome inflammatoire

TEP

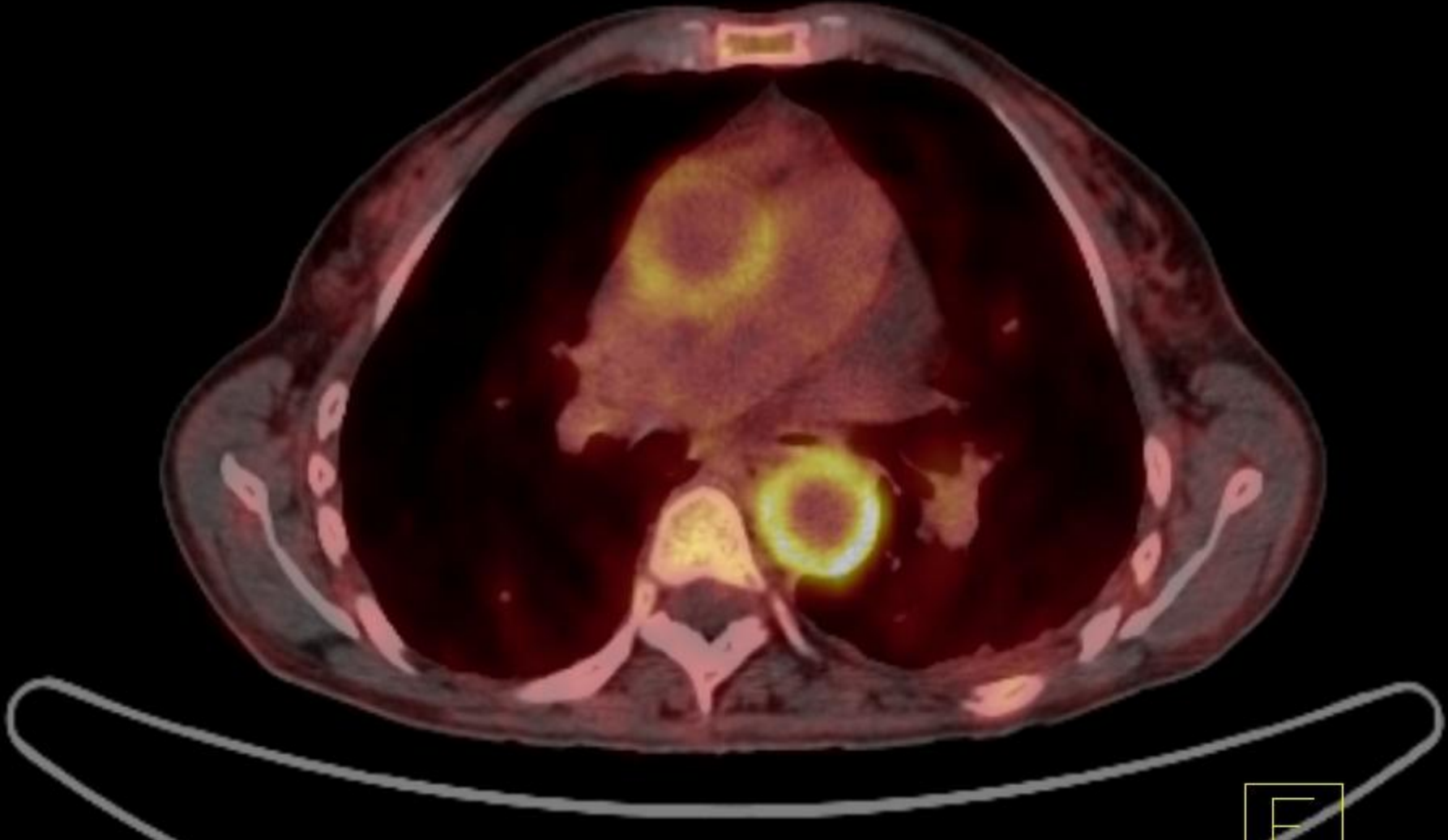
Spin: 0  
Tilt: -90



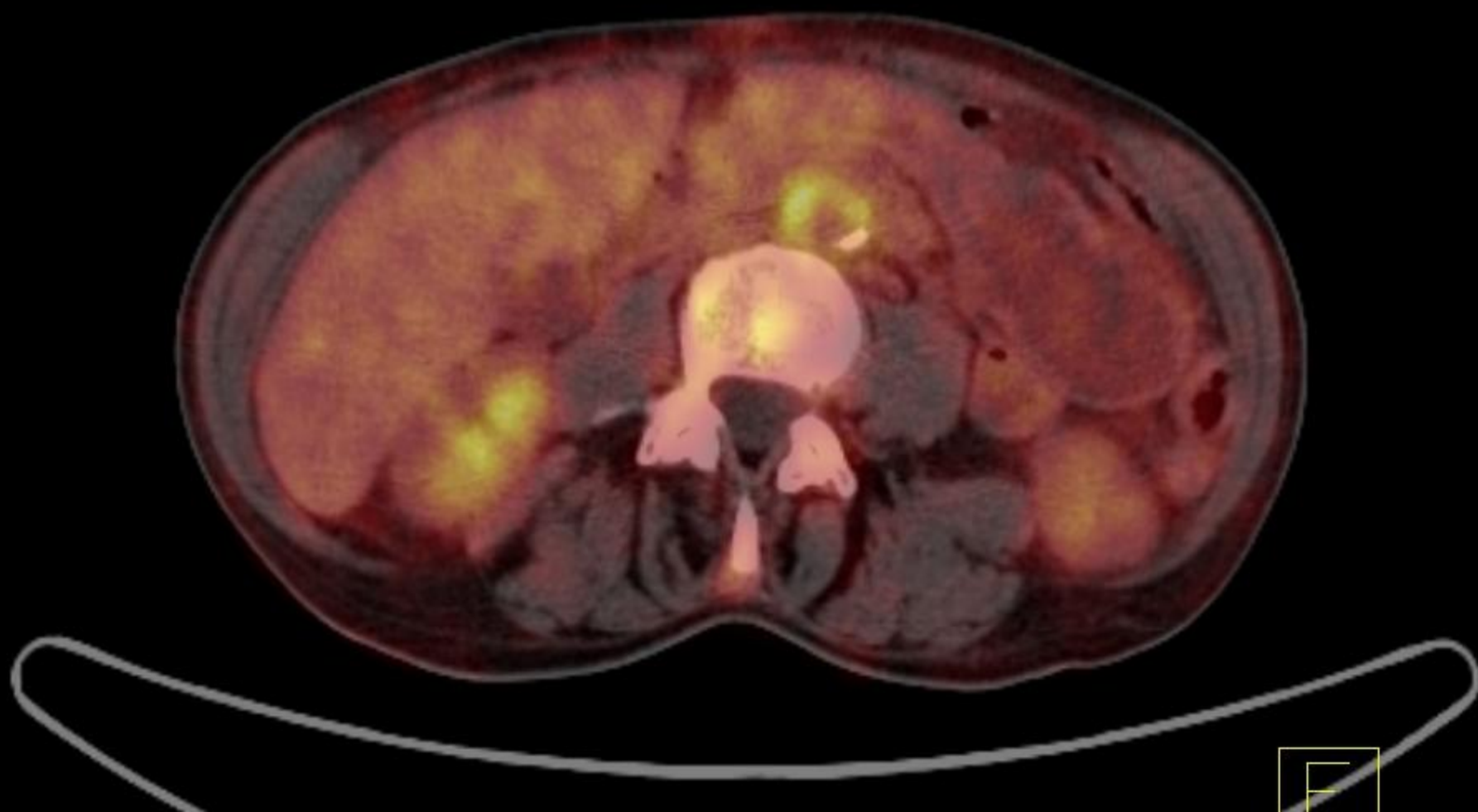
Spin: 0  
Tilt: -90

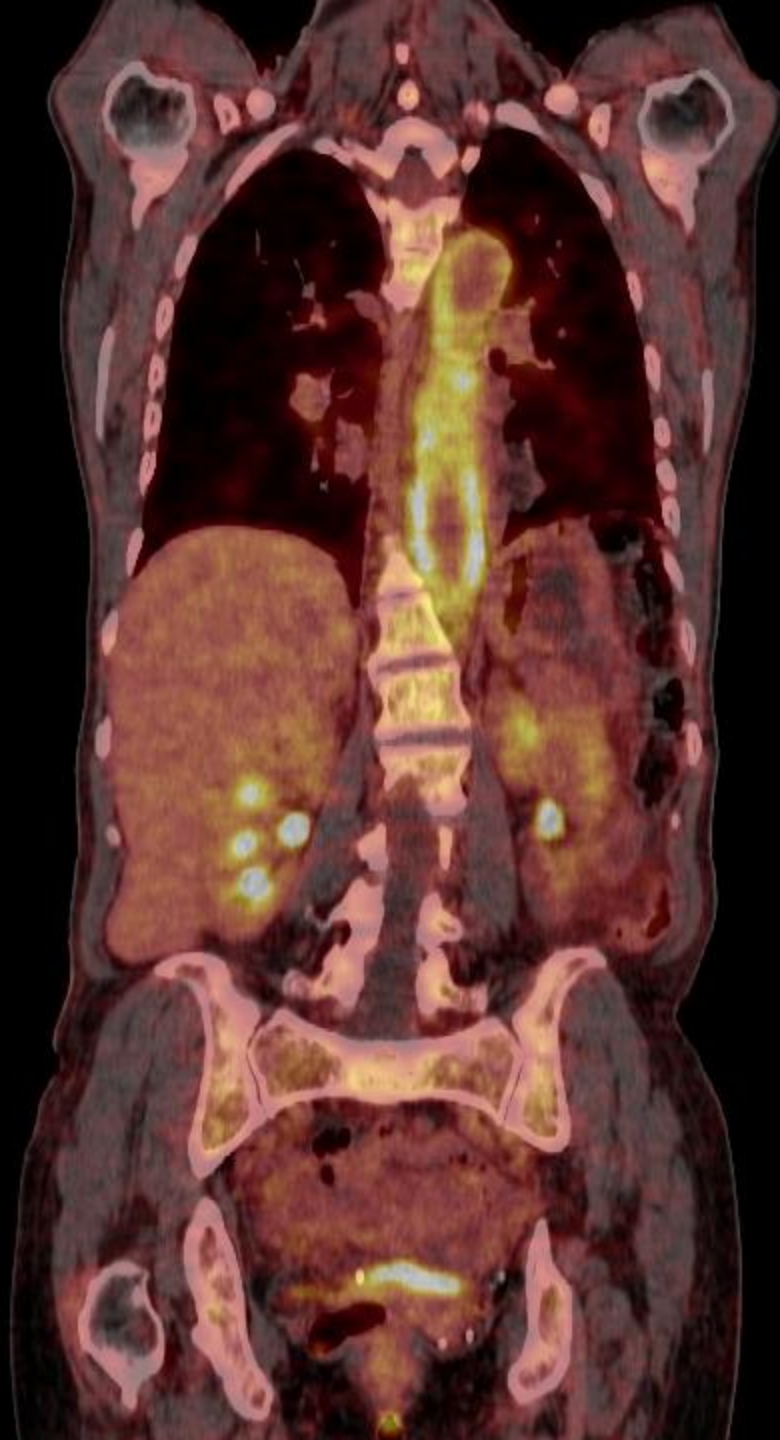


Spin: 0  
Tilt: -90



Spin: 0  
Tilt: -90





Spin: -0  
Tilt: 0

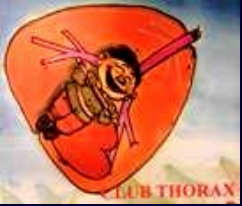



**Diagnostic ?**



# Maladie de HORTON



# Evolution-Discussion-Point fort

## Biopsie ARTERE TEMPORALE

**Intérêt TEP ? : diagnostic et évolutivité**



# Evolution-Discussion-Point fort

## Biopsie de l'ARTERE TEMPORALE

**DIFF / TAKAYASU :**

**Plus proximal**

**Atteinte de l'artère pulmonaire dans 50 % des cas**

**Terrain : femme de 40 ans**